




Giant bacillary angiomatosis



Authors:

Jeremy Nel¹ 
 Prudence Ive¹ 
 Carolina Nel² 

Affiliations:

¹Division of Infectious Diseases, Department of Medicine, Faculty of Health Sciences, University of the Witwatersrand, Johannesburg, South Africa

²Department of Anatomical Pathology, Faculty of Health Sciences, University of the Witwatersrand, National Health Laboratory Services, Johannesburg, South Africa

Corresponding author:

Jeremy Nel,
 jeremy.nel@wits.ac.za

Dates:

Received: 09 May 2021
 Accepted: 12 May 2021
 Published: 20 July 2021

How to cite this article:

Nel J, Ive P, Nel C. Giant bacillary angiomatosis. *S Afr J HIV Med.* 2021;22(1), a1257. <https://doi.org/10.4102/sajhivmed.v22i1.1257>

Copyright:

© 2021. The Authors.
 Licensee: AOSIS. This work is licensed under the Creative Commons Attribution License.

A 45-year-old female patient presented with a 2-month history of a progressively enlarging and ulcerating mass on her upper right chest wall, associated with weight loss of 20 kg (Figure 1a). The mass measured 12 cm in diameter and had become gradually more painful as the lesion expanded. The patient was newly diagnosed with HIV-1 infection, with a baseline CD4+ T-cell count of 10 cells/mm³ and a viral load of 38 000 copies/mL. Initially a diagnosis of non-Hodgkin's lymphoma was considered, but a biopsy revealed that the lesion consisted of a proliferation of capillaries lined by plump endothelial cells. A Warthin-Starry stain highlighted bacilli morphologically in keeping with *Bartonella* species (Figure 1b, arrows). An indirect immune fluorescence antibody assay for *Bartonella henselae* immunoglobulin G was strongly positive (> 1:256), and the biopsy sample tested positive for *Bartonella* by polymerase chain reaction, confirming the diagnosis of bacillary angiomatosis. Oral azithromycin therapy resulted in rapid improvement, with abatement of the pain within two days and regression of the lesion to half its original size within two weeks. Antiretroviral treatment was commenced simultaneously. Complete resolution of the lesion was accomplished after nine weeks of therapy, leaving only mild residual scarring (Figure 1c). To the best of our knowledge, this 12-cm lesion is the largest described in the literature to date.

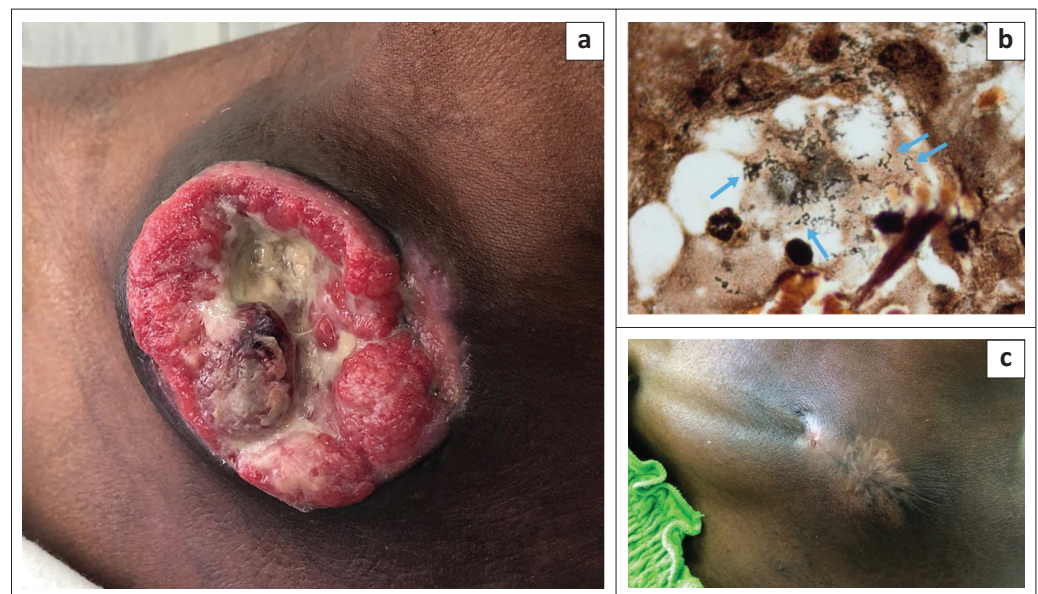

FIGURE 1: (a) The 20 cm ulcerating bacillary angiomatoma. (b) Warthin-Starry stain highlighting clumps of bacilli in keeping with *Bartonella* species. (c) Resolution of the lesion following 9 weeks of therapy.

Acknowledgements

Competing interests

The authors declare that they have no financial or personal relationships that may have inappropriately influenced them in writing this article.

Authors' contributions

J.N. drafted the manuscript. P.I. and C.N. reviewed the manuscript.

Read online:



Scan this QR code with your smart phone or mobile device to read online.

Ethical considerations

Ethical approval for this study was obtained from the University of the Witwatersrand's Human Research Ethics Committee (clearance number: M1909103).

Funding information

The authors received no financial support for the research or authorship of this article.

Data availability

Data sharing is not applicable to this article.

Disclaimer

The views and opinions expressed in this article are those of the authors and do not necessarily reflect the official policy or position of any affiliated agency of the authors.